

Phenol as an adjuvant for local control in the treatment of giant cell tumour of the bone

H. R. Dürr*, M. Maier*, V. Jansson*, A. Baur† and H. J. Refior*

*Department of Orthopedics and Orthopedic Surgery and †Institute of Radiology, Ludwig-Maximilians-University Munich, Klinikum Großhadern, D-81366 Munich, Marchioninistr. 15, Germany

Aims: Intralesional treatment of giant cell tumour (GCT) of the bone may result in a high rate of local recurrence. The introduction of local adjuvant therapy, such as cementation or phenolization, has led to a significant reduction in recurrence rates. Due to the combined use of phenol and cementation in most studies, the effect of phenol alone is described in this study.

Methods: Twenty primary and nine recurrent surgical procedures in 26 patients with GCT of the bone with a median follow-up of 61 months were reviewed retrospectively. The mean age was 33.5 years (range 13.5–76.5 years). Eighteen curettages and 11 resections were performed. For the curettages, a large bone window was cut followed by high speed burring and bone graft reconstruction. In 11 of 18 curettages and three of 12 resections, phenol was additionally applied.

Results: Four patients showed pulmonary metastasis. Three of these four cases also experienced local recurrences. Three patients died due to metastatic disease. In total, five patients developed local recurrence (17.2%); three in the first 2 years and one after 4 years. Four of 18 curettages recurred (22.2%), compared to one of 11 resections (9.1%). Only one of 11 patients (9.1%) treated with curettage and adjuvant phenol recurred, whereas three of seven patients (42.9%) treated with curettage alone recurred.

Conclusion: Phenolization is an effective and safe local adjuvant therapy for GCT. We did not observe any significant differences in recurrence rates for curettage, phenolization and bone grafting compared to most published results using cryosurgery or cementation alone. We recommend adjuvant phenolization in the treatment of GCT of the bone after careful curettage in applicable cases, regardless of whether additional cementation is used.

Key words: curettage; giant cell tumour; phenol.

© 1999 Harcourt Publishers Ltd

Introduction

Despite various techniques in the surgical treatment of giant cell tumour (GCT) of bone, recurrence rates as high as 50% have been reported.^{1–5} There is a strong correlation between the surgical margins and the rate of recurrence, dependent on whether intralesional curettage, marginal or wide resection is used.⁶ Due to the typical meta-epiphyseal location, however, wide resection may result in a major functional deficit. Hence, intralesional curettage has become the most recommended treatment.⁷

The introduction of local adjuvant therapy, such as cementation, cryosurgery or phenolization, in combination with careful removal of the tumour using a large bone window and high speed burrs has led to a significant reduction in recurrence rates.^{7–12} However, due to the combined use of phenol and cementation in most studies,

the effect of phenol alone is not well described. By comparing patients who were treated without adjuvant phenolization and bone grafting with those who were treated with adjuvant and bone grafting, we attempt here to overcome this void in the literature and describe the effect of phenol in the treatment of GCT.

Patients and methods

From October 1981 to February 1997, 26 patients were surgically treated in our institution for GCT of the bone. They consisted of 13 men and 13 women with a mean age of 33.5 years (13.5–76.5 years). Six patients presented who had already had local recurrence. As five patients experienced recurrence after the initial treatment, a second surgical procedure was performed in three of these patients in our institution. Two of the five recurrences were treated at different institutions. Therefore, 29 surgical procedures in 26 patients are reviewed in this study. In total, 20 primary and nine recurrent lesions were treated. Follow-up for all patients included radiographical and clinical evaluations

Correspondence to: Dr H. R. Dürr, Orthopädische Klinik und Poliklinik, Ludwig-Maximilians-Universität München, Klinikum Großhadern, D-81366 München, Marchioninistr. 15, Germany. Fax: +49 89/7095-8881; E-mail: hrduerr@ort.med.uni-muenchen.de.

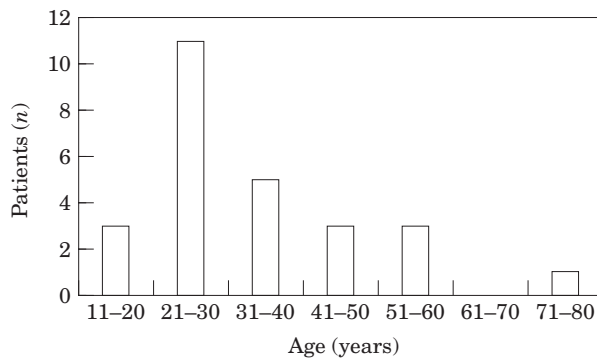


Fig. 1. Age distribution of 26 patients with giant cell tumour of the bone.

Table 1. Surgical procedures performed in 29 lesions

Therapy	
Curettage alone	1
Curettage and autologous graft	16
Curettage and homo-/autologous graft	1
Total	18
Resection alone	4
Resection and autologous graft	4
Resection and prosthesis	1
Resection and arthrodesis	2
Total	11

Table 2. Surgical procedures and the use of phenol in primary and recurrent cases

	Procedure	n	Phenol used (n/total)
Primary lesions (n=20)	Curettage	15	9/15
	Resection	5	2/5
Recurrent lesions (n=9)	Curettage	3	2/3
	Resection	6	1/6

performed by a physician in our institution or in the patients community. As MRI is much more sensitive for detecting local recurrence, this method was preferably used in addition to conventional radiographs. The median time to follow-up was 61 months (range: 6–178 months).

Results

Fig. 1 demonstrates that the highest incidence of GCT occurs in the third decade of life. As for location, the distal femur and the proximal tibia accounted for 14 of the 29 procedures (Fig. 2). Only three of the lesions involved the trunk, either the spine ($n=2$, Fig. 3) or the pelvis ($n=1$). Of the four tumours found in the foot, two were in the talus and one each in the calcaneus and the proximal metatarsal bone (Fig. 4).

In 26 of the 29 lesions, the patients reported associated pain. A swelling was found in nine cases, and neurological

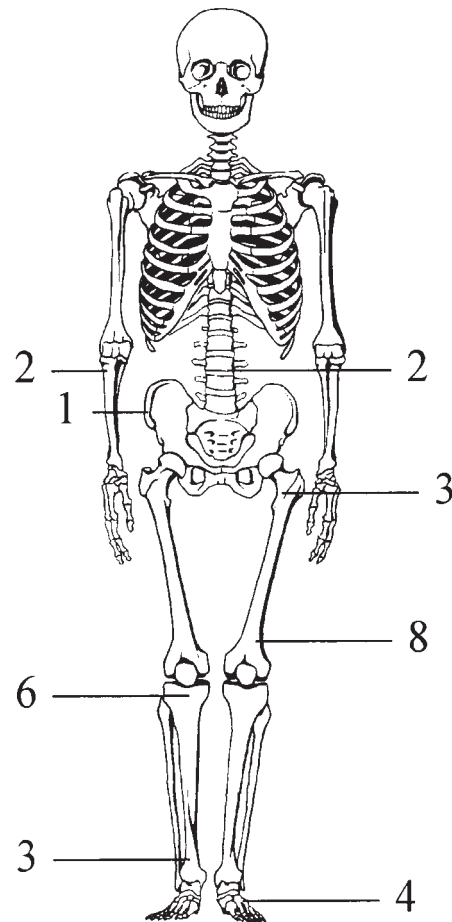


Fig. 2. Anatomical sites of the tumours in 29 surgical procedures.

impairment or a pathological fracture (Fig. 5) were found in one case each. Two lesions were found incidentally. The median duration of symptoms was 3.4 months (range: 3 weeks to 52 months).

Nine lesions (31%) showed joint involvement, whereas 15 (52%) showed subchondral involvement. Fifteen lesions were classified as active and 14 as aggressive, according to the Enneking staging system. Initial diagnosis, based on the typical radiographical findings of GCT, was confirmed by biopsy in all cases.

Eighteen curettages and 11 resections were performed. Twenty-three were classified as intralesional, two as marginal and four as wide (Table 1). For curettages, a large window was cut into the bone followed by high-speed burring. Phenol was used in 11 of the 18 curettages and in three of the 12 resections (Table 2). A solution of 50% phenol in 75% of alcohol¹³ was administered on swabs to the lesion for 1 min followed by irrigation with sodium bicarbonate and Ringer's solution. The defect was then reconstructed by autologous or homologous bone grafting (Fig. 6).

On admission, three patients had pulmonary metastases (11.5%). Two of these patients also had local recurrent disease. One 26-year-old patient underwent surgical resection of the tumour in both lungs, as well as in the bone, and was tumour-free 53 months after surgery (Fig. 7). The two other patients (41 and 76 years old,

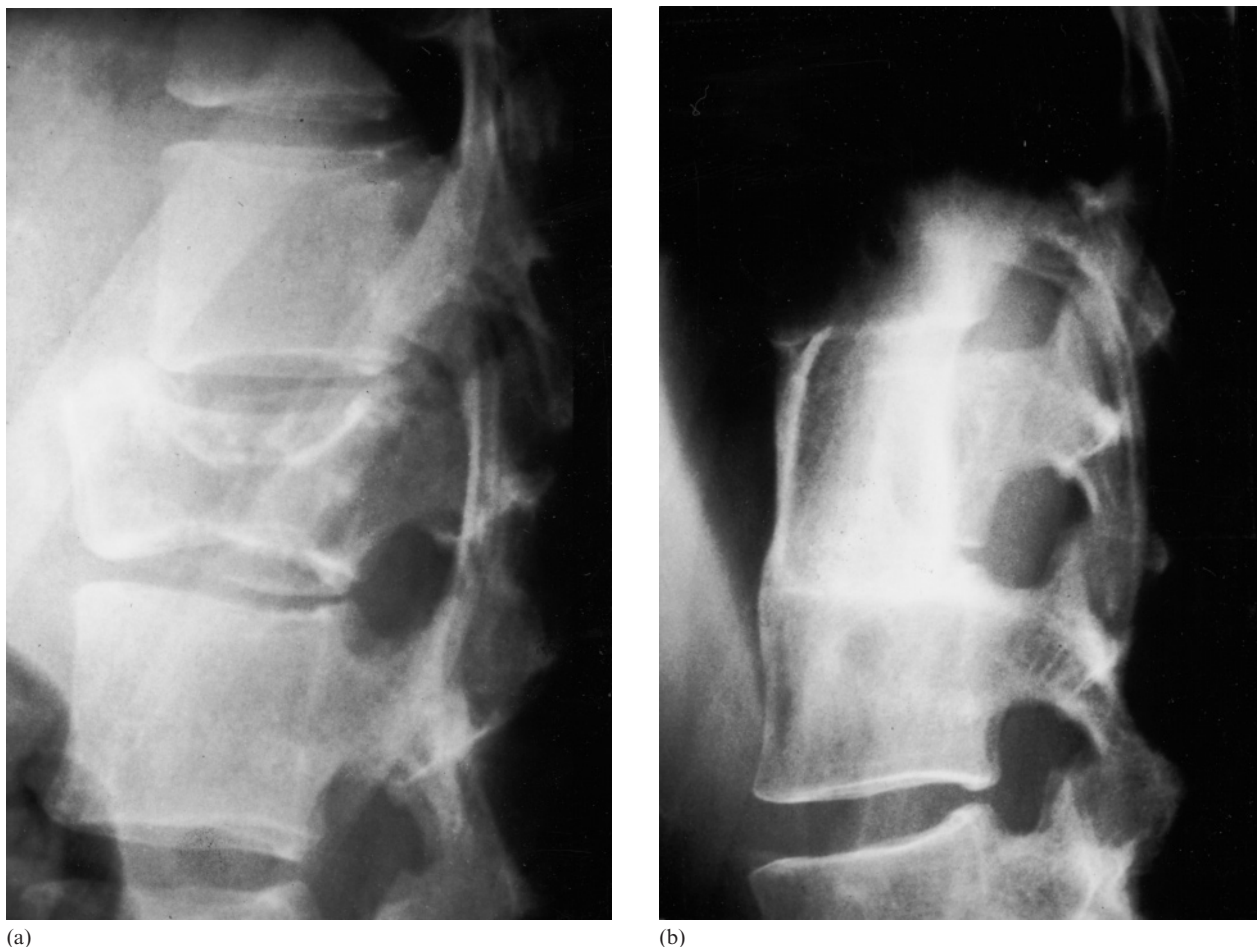

Fig. 3. (a) 24-year-old patient with pathological fracture of TH 11 due to a giant-cell tumour. The patient complained of radicular pain. (b) The same patient 13 years after partial resection of the vertebral body and fusion with a pelvic autograft.

Table 3. Recurrences in 29 surgical treated giant-cell tumours

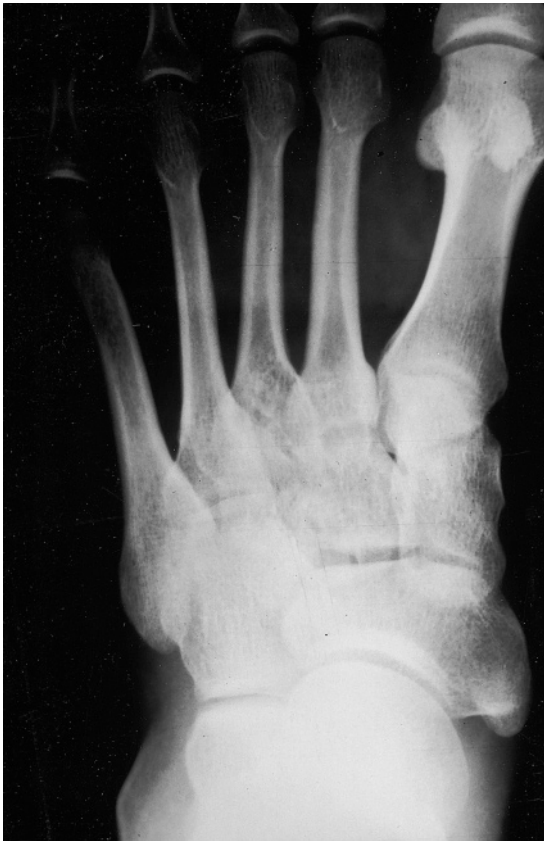	Recurrence (n)	Recurrence (%)	
Primary lesions (n=20)	3	15.0%	$p=0.634$
Recurrent lesions (n=9)	2	22.2%	
Total (n=29)	5	17.2%	
Curettages (n=18)	4	22.2%	$p=0.364$
Resections (n=11)	1	9.1%	
Curettages and phenol (n=11)	1	9.1%	$p=0.093$
Curettages no phenol (n=7)	3	42.9%	

respectively) died 4 and 5 months after local surgery due to disseminated pulmonary disease. In follow-up, a 32-year-old patient who had been treated for a local recurrent tumour 10 years prior to admission also developed pulmonary metastasis and died 7 months later. Thus, in our

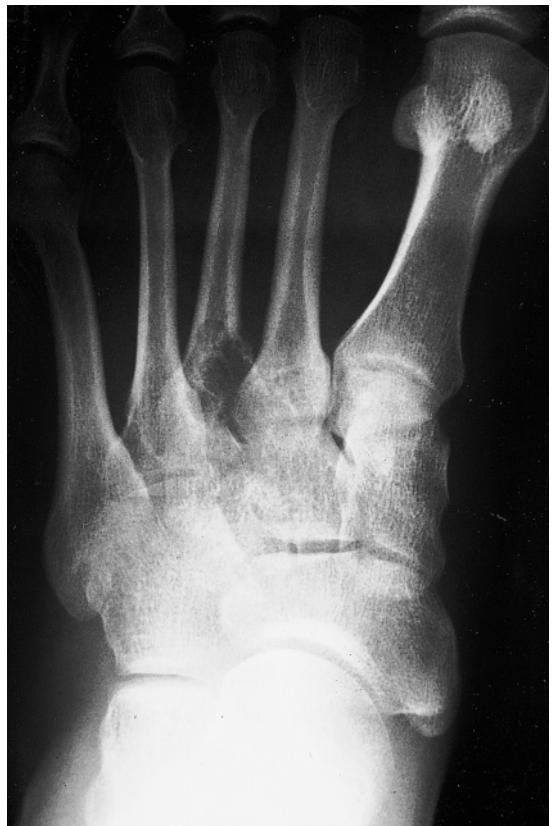patient group, four of 29 (13.8%) treated patients presented with or developed pulmonary metastasis in the course of the disease. Three of these four cases also experienced local recurrences.

At follow-up, three patients died, as described above.

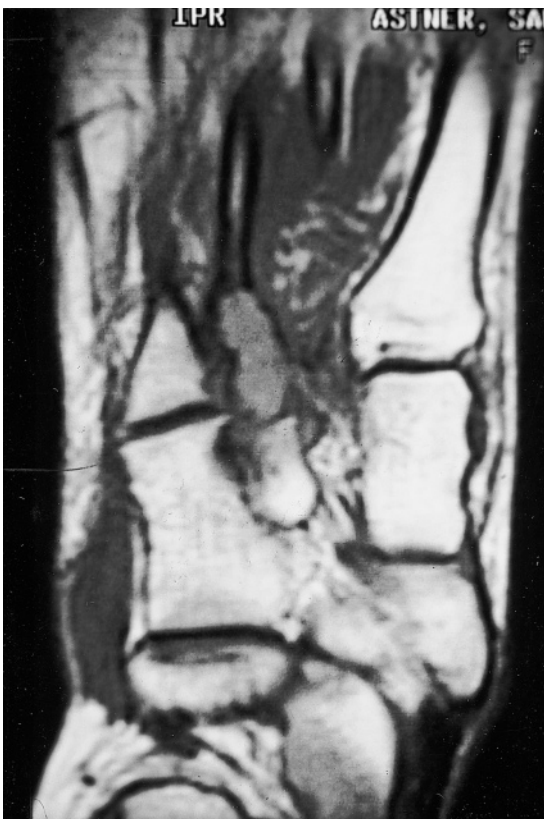
Fig. 4. (Opposite page) (a,b) 24-year-old patient complaining of pain in the left metatarsus. Radiographs obtained at initial presentation and 15 months later. A progressive excentric meta-epiphyseal osteolysis of the proximal third metatarsal is obvious. (c) MR image showing a destructive lesion of the proximal third metatarsal confined to the bone but extending subchondrally close to the joint. (d) After resection, interposition of a pelvic autograft and arthrodesis of the joint. The patient is free of tumour 30 months after surgery.



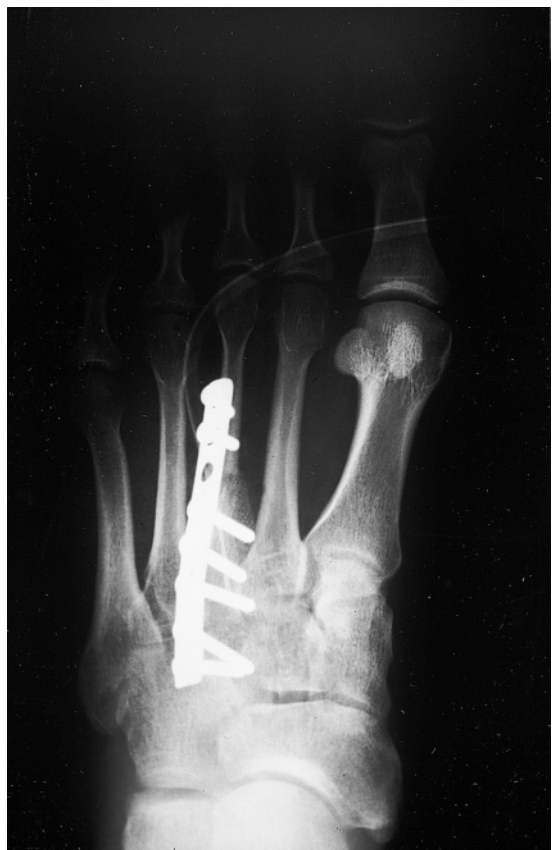(a)



(b)



(c)



(d)

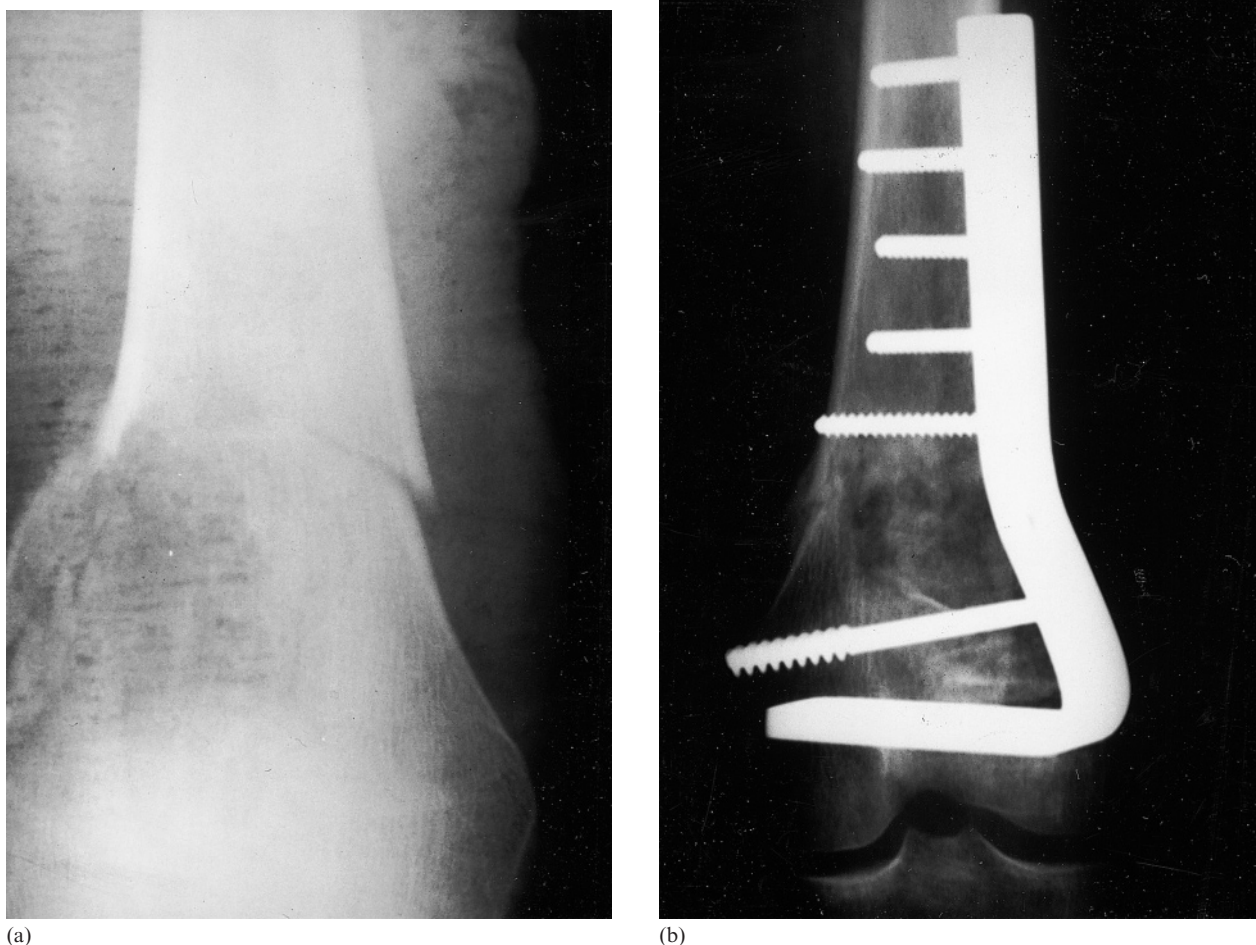


Fig. 5. (a) 16-year old girl with a pathological fracture of the distal femur due to a previously asymptomatic giant-cell tumour. Initial radiographs at presentation show the excentric large osteolytic destruction with a displaced fracture. (b) The same patient after curettage of the lesion, bone grafting and osteosynthesis. The patient is free of tumour 14 years after surgery.

Two of them were initially treated outside our department with recurrences after local surgery. These treatments were not included in the 29 procedures reviewed in our study because they were not performed in our institution.

Of the 29 surgical procedures performed in our institution, five patients developed local recurrences (17.2%). Recurrence developed in a case of resection with intralesional margins without the use of phenol. Only one patient out of 11 (9.1%) who had been treated with curettage and adjuvant phenol developed a recurrence, whereas three patients out of seven (42.9%) who had been treated with curettage without phenol developed a recurrence (Table 3). This was a clear tendency but did not reach statistical significance. The time between the initial surgical procedure and recurrence for all patients is shown in Fig. 8. Four of the five lesions recurred in the first 2 years and one after 4 years.

Discussion

Giant cell tumour of the bone accounts for approximately 8.6% of all bone tumours.¹⁴ Interestingly, China seems to have the highest incidence, at 20%.⁵ Most of the lesions reportedly occur in patients in the third or fourth decade

of life, corresponding to our own findings. Only three patients in our study group were outside this age range. Despite an equal male to female ratio in this study, gender seems to be unevenly distributed in larger series that show a female preponderance for GCT.^{3,15} The most frequent tumour site in our study was the lower end of the femur and the proximal tibia, corresponding to the results of other groups who have reported that approximately 50% of tumours occur around the knee.^{14,16} The typical meta- and epiphyseal involvement was seen in all patients, while no patient showed the rare meta-diaphyseal extension.¹⁷

Conventional histological grading has been shown to be of limited value in predicting clinical outcome.^{3,18-22} In recent studies, the spindle-shaped stroma cells proved not only to be the major proliferating cells in the tumour,²³ but also their proliferation rate was associated with the radiographical aggressiveness of the tumour.²⁴ Additional factors, such as expression of metalloproteinases, may gain clinical importance,²⁵ whereas others, such as DNA analysis, show conflicting results.²⁶⁻²⁸

Pain was the most common clinical symptom (90%). Swelling developed in only 31% of the patients. The duration of complaints varied greatly, corresponding to the unpredictable course of the tumour.¹⁶

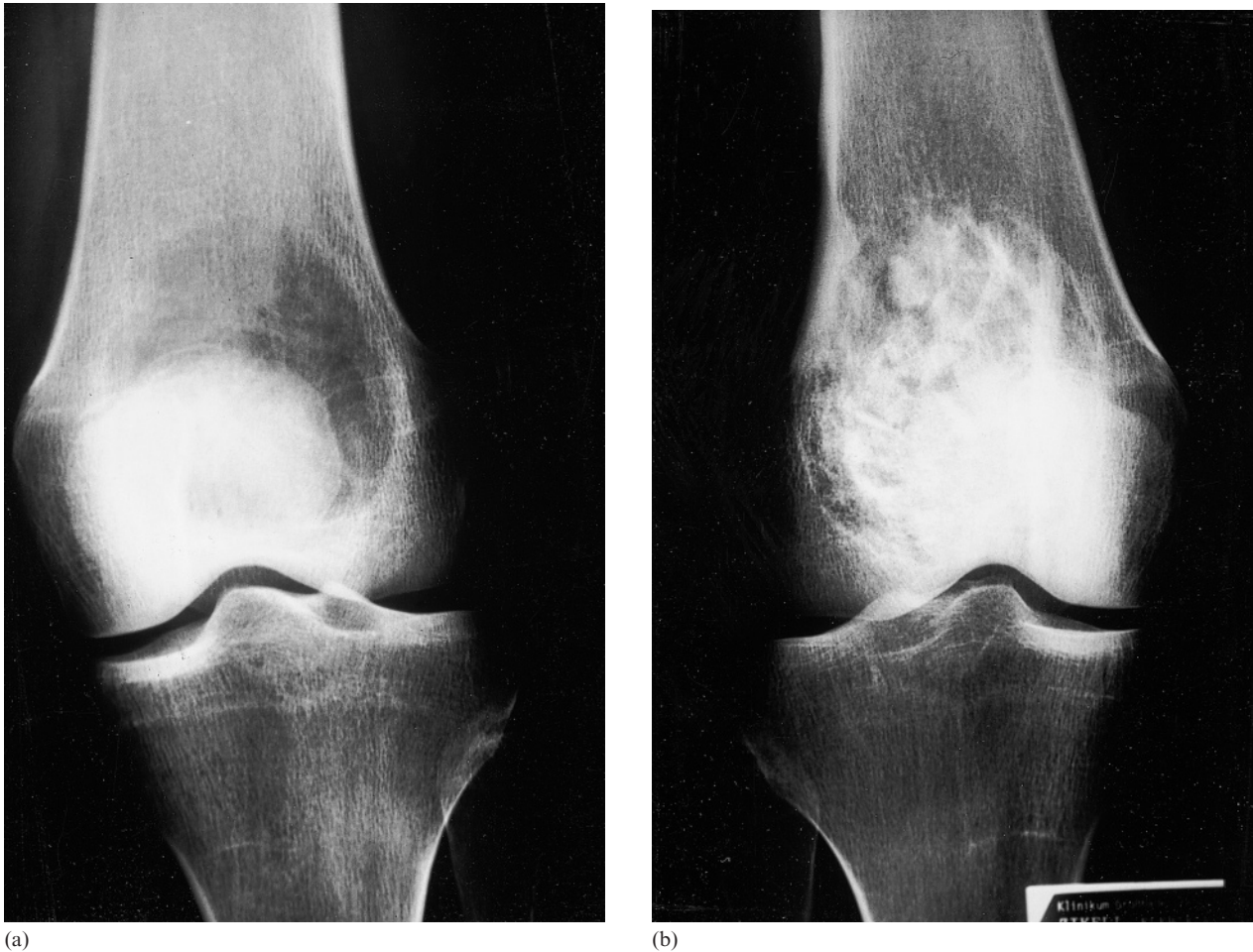


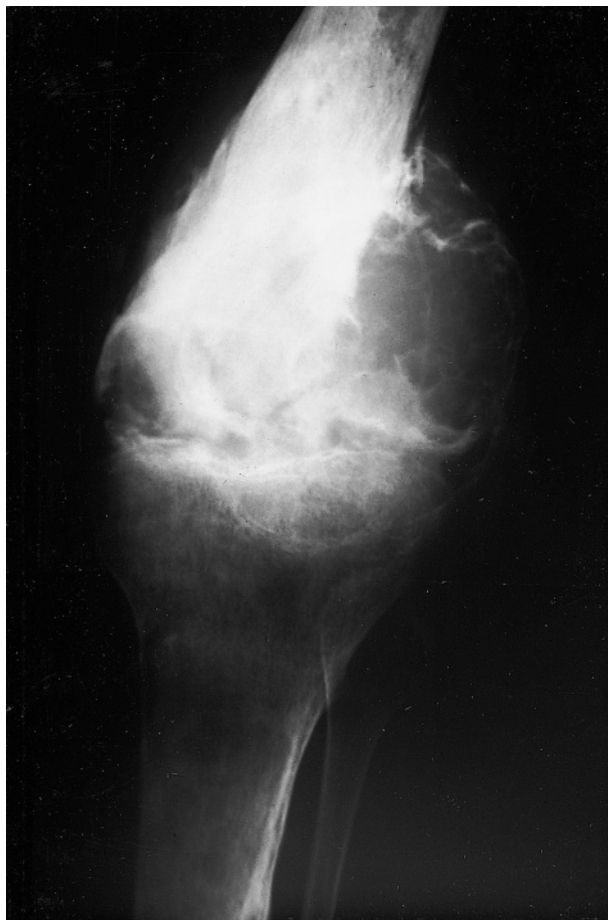
Fig. 6. (a) 25-year old patient with giant-cell tumour of the distal femur. Radiograph showing a large epi-metaphyseal osteolysis extending close to the joint. (b) The same patient 3 years after curettage, phenolization and autologous bone grafting of the lesion. The patient is free of tumour and symptoms.

Although GCT is classified as benign, pulmonary metastasis is found in approximately 3–10% of cases.^{20,29–36} The fact that our institution is a referral centre for interdisciplinary approaches in bone tumour may explain the higher frequency of metastasis found in our institution. Histology has proven that GCT tends to infiltrate peripheral veins, allowing the tumour to spread to distant locations.³⁷ Pulmonary metastasis develops preferentially in recurrent cases, as demonstrated in our series (three of four patients).³⁷ Although the overall survival of these patients surpasses that of patients with other bone tumours with secondary pulmonary metastasis, in general 10–20% of the patients die from their disease.^{20,29,35,36} Due to extensive tumour spread, three of our four cases died 4–7 months after diagnosis. Because of the unpredictable nature of the tumour, however, one may also observe a long asymptomatic course of disease, despite extensive metastasis.³²

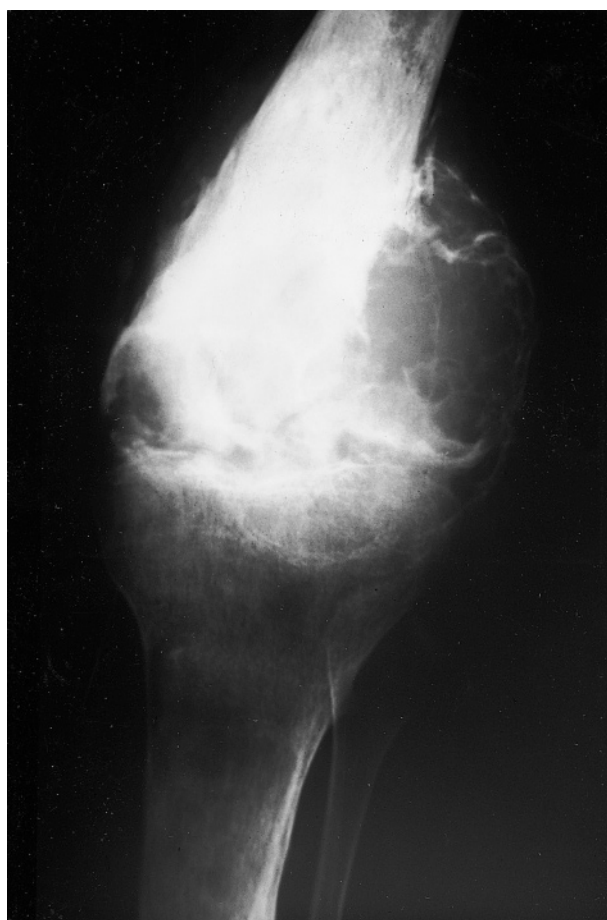
The remarkable local aggressiveness of GCT as a benign bone tumour continues to be a surgical challenge. Until 1912, amputation was the preferred method of treatment, at which time intralesional resection and bone grafting was introduced.³⁸ With no further treatment, local recurrence may develop in 80% in such cases.³ There is no doubt that wide resection reduces the risk of recurrence, as shown in

our cases, but due to the anatomical location of the tumour, a less destructive approach is often desirable. Several methods of adjuvant treatment have been advocated. Radiation therapy, first described by Ewing,³⁹ is associated with a high rate of secondary malignancies and is no longer applicable in routine cases. Cryosurgery, introduced in 1964, showed recurrence rates of less than 10%, but was also associated with considerable complications, such as fractures and delayed bone and wound healing.^{8,40} In recent reports acceptable complication rates were described.^{41–43} In reports by groups who used additional cementation, the results were favourable.^{12,44,45} Acrylic cementation combines the local effect of hyperthermia and the immediate stabilization of the defect without further surgery for bone graft harvesting.^{46–48} In a series of 38 consecutive patients, a recurrence rate of 8% was reported using this technique.¹⁰ A negative influence of acrylic cementation to the adjacent joint cartilage was not observed.⁴⁹ Another method based on the hyperthermic approach, CO₂ laser cauterization, is currently being evaluated.⁵⁰

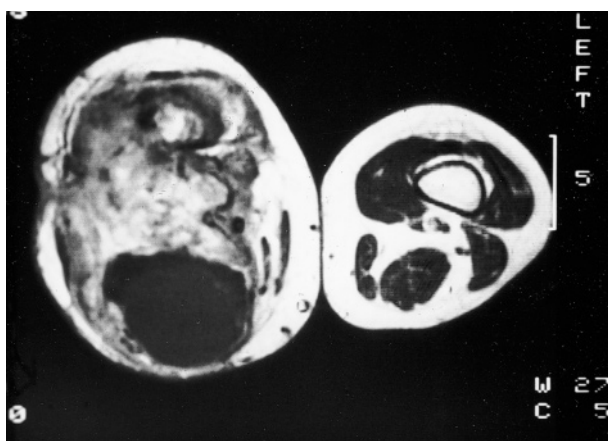
Since its introduction for the elimination of recurrences in benign tumours,⁵¹ a local application of phenol has been commonly used in the treatment of GCT.⁵² Most authors use both phenol and acrylic cementation in GCT of the



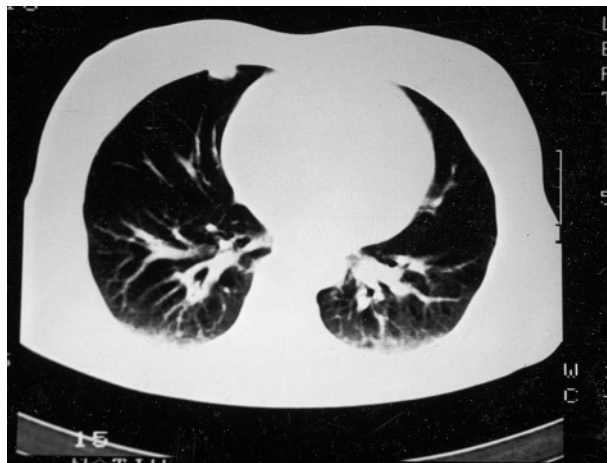
(a)



(b)



(c)



(d)

Fig. 7. (a,b) 26-year-old patient 7 years after initial surgery complaining of pain and swelling of the distal femur of 4 year's standing. Radiographs obtained after angiography showing the large destructive giant-cell tumour. (c) Axial MR image showing the extent of the tumour infiltrating the popliteal vessels. An amputation had to be performed. (d) CT scan of the same patient showing multiple pulmonary metastasis. After bilateral metastasectomy, the patient is free of tumour 4 years after surgery.

bone.⁵³ Only two large studies by the same study group have provided data on the use of phenolization alone in the treatment of GCT.^{52,53} In the first study, 69 patients were treated with adjuvant phenol applied with swabs and 14 patients were treated with autologous or homologous bone grafting. In this series, one recurrence was seen after the

application of phenol (7%), whereas recurrence occurred in 26 of 55 patients without phenolization (47%). In a later series, recurrence was observed in 45% of 280 cases without further adjuvant treatment and in 17% of patients treated with either additional phenol ($n=147$), liquid nitrogen ($n=20$) or cement ($n=187$) without significant differences in the

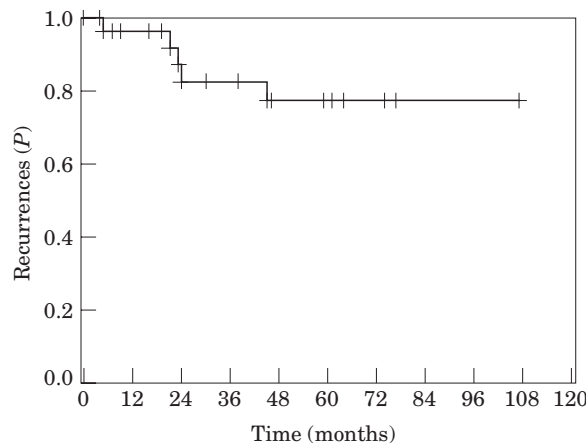


Fig. 8. Recurrences in 29 patients treated surgically for giant-cell tumour of the bone.

subgroups. These data correspond very well with our own recurrence rate of 42% without phenol and 9% with phenol. Remarkably, in the study of Capanna *et al.*, the combination of phenol and cementation reduced the recurrence rate to 3% in 33 patients.

We conclude that phenolization is an effective and safe local adjuvant therapy for GCT, comparable to other methods such as cryosurgery. Based on our data, there is no significant difference in recurrence rate for curettage, phenolization alone or bone grafting when compared to the results of the studies using cementation. We recommend adjuvant phenolization in the treatment of GCT of bone after curettage in all applicable cases whether further cementation is used or not.

Acknowledgements

This report was supported by the Curt-Bohnewand-Fund.

References

- McDonald DJ, Sim FH, McLeod RA, Dahlin DC. Giant-cell tumor of bone. *J Bone Joint Surg (Am)* 1986; **68**: 235–42.
- Dahlin DC, Cupps RE, Johnson EW, Jr. Giant-cell tumor: a study of 195 cases. *Cancer* 1970; **25**: 1061–70.
- Goldenberg RR, Campbell CJ, Bonfiglio M. Giant-cell tumor of bone. An analysis of two hundred and eighteen cases. *J Bone Joint Surg (Am)* 1970; **52**: 619–64.
- Mnaymneh WA, Ghandur-Mnaymneh L. Giant-cell tumor of bone. *Prog Clin Cancer* 1967; **3**: 245–80.
- Sung HW, Kuo DP, Shu WP, Chai YB, Liu CC, Li SM. Giant-cell tumor of bone: analysis of two hundred and eight cases in Chinese patients. *J Bone Joint Surg (Am)* 1982; **64**: 755–61.
- Campanacci M, Baldini N, Boriani S, Sudanese A. Giant-cell tumor of bone. *J Bone Joint Surg (Am)* 1987; **69**: 106–14.
- Eckardt JJ, Grogan TJ. Giant cell tumor of bone. *Clin Orthop* 1986; **204**: 45–58.
- Jacobs PA, Clemency RE, Jr. The closed cryosurgical treatment of giant cell tumor. *Clin Orthop* 1985; **192**: 149–58.
- Pang Fu K, Pu Fan C, Hua Feng T, Tsai Wei S. Cryosurgery in giant cell tumor of bone. *Chinese Med J Engl* 1979; **92**: 125–28.
- Bini SA, Gill K, Johnston JO. Giant cell tumor of bone. Curettage and cement reconstruction. *Clin Orthop* 1995; **321**: 245–50.
- Komiya S, Inoue A. Cementation in the treatment of giant cell tumor of bone. *Arch Orthop Trauma Surg* 1993; **112**: 51–5.
- Pals SD, Wilkins RM. Giant cell tumor of bone treated by curettage, cementation, and bone grafting. *Orthopedics* 1992; **15**: 703–8.
- Lack W, Lang S, Brand G. Necrotizing effect of phenol on normal tissues and on tumors. *Acta Orthop Scand* 1994; **65**: 351–4.
- Schajowicz F. Giant-cell tumor (osteoclastoma). In: *Tumors and tumorlike lesions of bone*. Berlin, Heidelberg, New York: Springer-Verlag, 1994: 257–99.
- Dahlin DC. Caldwell Lecture. Giant cell tumor of bone: highlights of 407 cases. *AJR* 1985; **144**: 955–60.
- Campanacci M. Giant cell tumor. In: *Bone and soft tissue tumors*. Wien, New York: Springer-Verlag, 1990: 117–51.
- Fain JS, Unni KK, Beabout JW, Rock MG. Non-epiphyseal giant cell tumor of the long bones. Clinical, radiologic, and pathologic study. *Cancer* 1993; **71**: 3514–9.
- Larsson SE, Lorentzon R, Boquist L. Giant-cell tumor of bone. A demographic, clinical, and histopathological study of all cases recorded in the Swedish Cancer Registry for the years 1958 through 1968. *J Bone Joint Surg (Am)* 1975; **57**: 167–73.
- Sanerkin NG. Malignancy, aggressiveness, and recurrence in giant cell tumor of bone. *Cancer* 1980; **46**: 1641–9.
- Rock MG, Pritchard DJ, Unni KK. Metastases from histologically benign giant-cell tumor of bone. *J Bone Joint Surg (Am)* 1984; **66**: 269–74.
- Schiodt T, Dissing I, Heerfordt J, Sneppen O. [Giant cell tumor of bone. Assessment of degree of malignancy in relationship to microscopic findings] Kaempecelletumor i knogle. En vurdering af maligniteten i relation til mikroskopifund. *Ugeskr Laeger* 1978; **140**: 1613–5.
- Lausten GS, Jesen PK, Schiodt T, Lund B. Local recurrences in giant cell tumour of bone. Long-term follow up of 31 cases. *Int Orthop* 1996; **20**: 172–6.
- Huang J, Hu S, Huang P, Shi N, Gao M, Saito M, Mori M. Immunohistochemical evaluation of giant cell tumor of the bone. *Acta Histochem Cytochem* 1996; **29**: 107–13.
- Robinson D, Lewis MM, Nevo Z, Kenan S, Einhorn TA. The radiographic stage of giant cell tumor related to stromal cells' proliferation. Tissue cultures in 13 cases. *Acta Orthop Scand* 1997; **68**: 294–7.
- Schoedel KE, Greco MA, Stetler Stevenson WG, Ohori NP, Goswami S, Present D, Steiner GC. Expression of metalloproteinases and tissue inhibitors of metalloproteinases in giant cell tumor of bone: an immunohistochemical study with clinical correlation. *Hum Pathol* 1996; **27**: 1144–8.
- Zhou L, Feng CH, Zhang HF. [Flow cytometric analysis of DNA in giant cell tumor of bone] (in Chinese). *Chung Hua Wai Ko Tsa Chih* 1994; **32**: 367–70.
- Scott SM, Pritchard DJ, Unni KK, Rainwater LM, Lieber MM. "Benign" metastasizing giant cell tumor: evaluation of nuclear DNA patterns by flow cytometry. *J Orthop Res* 1989; **7**: 463–7.
- Helio H, Karaharju E, Bohling T, Nordling S. Giant cell tumours of bone. A DNA-flow cytometric study. *Eur J Surg Oncol* 1994; **20**: 200–6.
- Siebenrock KA, Unni KK, Rock MG. Giant-cell tumour of bone metastasising to the lungs. A long-term follow-up. *J Bone Joint Surg (Br)* 1998; **80**: 43–7.
- Cheng JC, Johnston JO. Giant cell tumor of bone. Prognosis and treatment of pulmonary metastases. *Clin Orthop* 1997; **338**: 205–14.
- Osaka S, Toriyama M, Taira K, Sano S, Saotome K. Analysis of giant cell tumor of bone with pulmonary metastases. *Clin Orthop* 1997; **335**: 253–61.
- Kay RM, Eckardt JJ, Seeger LL, Mirra JM, Hak DJ. Pulmonary metastasis of benign giant cell tumor of bone. Six histologically confirmed cases, including one of spontaneous regression. *Clin Orthop* 1994; **302**: 219–30.
- Tubbs WS, Brown LR, Beabout JW, Rock MG, Unni KK. Benign giant-cell tumor of bone with pulmonary metastases:

- clinical findings and radiologic appearance of metastases in 13 cases. *AJR* 1992; **158**: 331–4.
34. Maloney WJ, Vaughan LM, Jones HH, Ross J, Nagel DA. Benign metastasizing giant-cell tumor of bone. Report of three cases and review of the literature. *Clin Orthop* 1989; **243**: 208–15.
 35. Bertoni F, Present D, Sudanese A, Baldini N, Bacchini P, Campanacci M. Giant-cell tumor of bone with pulmonary metastases. Six case reports and a review of the literature. *Clin Orthop* 1988; **237**: 275–85.
 36. Bertoni F, Present D, Enneking WF. Giant-cell tumor of bone with pulmonary metastases. *J Bone Joint Surg (Am)* 1985; **67**: 890–900.
 37. Caballes RL. The mechanism of metastasis in the so-called “benign giant cell tumor of bone”. *Hum Pathol* 1981; **12**: 762–7.
 38. Bloodgood JC. The conservative treatment of giant-cell sarcoma with the study of bone transplantation. *Ann Surg* 1912; **56**: 210–39.
 39. McCarthy EF. Giant-cell tumor of bone: an historical perspective. *Clin Orthop* 1980; **153**: 14–25.
 40. Marcove RC, Weis LD, Vaghaiwalla MR, Pearson R. Cryosurgery in the treatment of giant cell tumors of bone: a report of 52 consecutive cases. *Clin Orthop* 1978; **134**: 275–89.
 41. Malawer MM, Bickels J, Meller I, Buch RG, Henshaw RM, Kollender Y. Cryosurgery in the treatment of giant cell tumor. *Clin Orthop* 1999; **359**: 176–88.
 42. Schreuder HWB, Veth RPH, Pruszczynski M, Lemmens JAM, Koops HS, Molenaar M. Aneurysmal bone cysts treated by curettage, cryotherapy and bone grafting. *J Bone Joint Surg (Br)* 1997; **79-B**: 20–5.
 43. Schreuder HWB, Pruszczynski M, Veth RPH, Lemmens JAM. Treatment of benign and low-grade malignant intramedullary chondroid tumours with curettage and cryosurgery. *Eur J Surg Oncol* 1998; **24**: 120–6.
 44. Freith R. Side effects of acrylic cement implanted into bone. *Acta Orthop Scand* 1975 (Suppl.) 161: 1–130.
 45. Malawer MM, Dunham WK. Cryosurgery and acrylic cementation as surgical adjuncts in the treatment of aggressive (benign) bone tumors: analysis of 25 patients below the age of 21. *Clin Orthop* 1991; **262**: 42–57.
 46. Persson BM, Wouters HW. Curettage and acrylic cementation in surgery of giant cell tumors of bone. *Clin Orthop* 1976; **120**: 125–33.
 47. Quint U. Recurrence of giant-cell tumour of bone after the use of cement. *J Bone Joint Surg (Br)* 1998; **80**: 370.
 48. Härle A, Wuisman P. [Curettage of giant cell tumors with temporary implantation of bone cement] Die Kürettage von Riesenzelltumoren mit temporärer Implantation von Knochenzement. *Z Orthop* 1989; **127**: 382–6.
 49. Persson BM, Ekelund L, Lövdahl R, Gunterberg B. Favourable results of acrylic cementation for giant cell tumors. *Acta Orthop Scand* 1984; **55**: 209–14.
 50. Kenan S, Kirby EJ, Buchalter J, Lewis MM. The potential role of the laser in marginal sterilization of giant cell tumor following curettage. *Bull Hosp Jt Dis Orthop Inst* 1988; **48**: 93–101.
 51. Bloodgood JC. Benign bone cysts, osteitis fibrosa, giant cell sarcoma and bone aneurysms of the long pipe bones. *Ann Surg* 1910; **52**: 145–85.
 52. Capanna R, Sudanese A, Baldini N, Campanacci M. Phenol as an adjuvant in the control of local recurrence of benign neoplasms of bone treated by curettage. *Ital J Orthop Traumatol* 1985; **11**: 381–8.
 53. Capanna R, Fabbri N, Betelli G. Curettage of giant cell tumor of bone. The effect of surgical technique and adjuvants on local recurrence rate. *Chir Organi Mov* 1990; **75** (Suppl.): 206.

Accepted for publication 6 May 1999