

Radiofrequency ablation in the treatment of osteoid osteoma—5-year experience

Ralf-Thorsten Hoffmann^{a,*}, Tobias F. Jakobs^{a,1}, Constanze H. Kubisch^{b,2}, Christoph G. Trumm^{a,1}, Christof Weber^{c,3}, Hans-Roland Duerr^{d,4}, Thomas K. Helmberger^{c,5}, Maximilian F. Reiser^{a,1}

^a Institute of Clinical Radiology, Ludwig Maximilians-University, Campus Grosshadern, Marchioninistrasse 15, 81377 Munich, Germany

^b Department of Medicine/Gastroenterology, Ludwig Maximilians-University, Campus Grosshadern, Marchioninistrasse 15, 81377 Munich, Germany

^c Institute of Radiology and Nuclear Medicine, Klinikum Bogenhausen, Engelschalkinger Str. 77; 81925 Munich, Germany

^d Department of Orthopedic Surgery, Ludwig Maximilians-University, Campus Grosshadern, Marchioninistrasse 15, 81377 Munich, Germany

^e Institute of Diagnostic and Interventional Radiology, Klinikum – Deggendorf, Perlasbergerstr. 41, 94469 Deggendorf, Germany

ARTICLE INFO

Article history:

Received 21 August 2008

Received in revised form 31 October 2008

Accepted 21 November 2008

Keywords:

RFA

Thermal ablation

Osteoid osteoma

CT fluoroscopy

Biopsy

ABSTRACT

Purpose: This study aimed to determine the success and complication rates of radiofrequency ablation (RFA) in treatment of osteoid osteoma (OO) and duration of pain relief. Furthermore value of bone biopsy prior to the RFA was evaluated.

Materials and methods: Within 61 months 39 patients (23 male, 16 female, 7–53 years, mean 18.7 years, median 17 years) suffering from osteoid osteoma were treated. Lesions were located in femur ($n=20$), tibia ($n=10$), spine ($n=5$), humerus ($n=1$), radius ($n=1$), talus ($n=1$) and pelvis ($n=1$). In children, RFA was performed under general anaesthesia, in adults conscious sedation was preferred. In 29 of 39 (74%) lesion biopsies were obtained. Cooling of skin was performed in OOs located in bones with minor soft tissue covering (tibia, radius) and saline flushing via an additional needle was performed if the OO was adjacent to neural structures. Primary success rate, complications, symptom-free interval, follow-up and biopsy results were evaluated.

Results: Within observation period (1–61 months; median: 32 months) 38 of 39 patients were successfully treated and had no more complaints. In 3 of 38 patients relapse occurred after 1, 14 and 32 months and RFA was repeated. Two major complications (broken drill, infection) and 2 minor complications (hematoma, prolonged pain) were observed. Biopsy was able to prove diagnosis in 14 of 29 (48%) cases.

Conclusions: Biopsy prior to treatment is not mandatory due to a remarkable amount of false negative findings in clinically and morphologically unambiguous cases of OO. RFA is a highly effective, efficient, minimally invasive and safe method for the treatment of OO.

© 2008 Elsevier Ireland Ltd. All rights reserved.

1. Introduction

Osteoid osteoma (OO), first described in 1935 by Jaffe, is a slowly growing, benign, round lesion of the bone which is characterized

* Corresponding author. Tel.: +49 89 7095 3620; fax: +49 89 7095 8832.

E-mail addresses: rthoffma@med.uni-muenchen.de, ralf-thorsten.hoffmann@med.uni-muenchen.de (R.-T. Hoffmann), tobias.jakobs@med.uni-muenchen.de (T.F. Jakobs), constanze.kubisch@med.uni-muenchen.de (C.H. Kubisch), christoph.trumm@med.uni-muenchen.de (C.G. Trumm), privat@christofweber.de (C. Weber), hduerr@med.uni-muenchen.de (H.-R. Duerr), thomas.helmberger@kh-bogenhausen.de (T.K. Helmberger), maximilian.reiser@med.uni-muenchen.de (M.F. Reiser).

¹ Tel.: +49 89 7095 2750; fax: +49 89 7095 8832.

² Tel.: +49 89 7095 3130; fax: +49 89 7095 5264.

³ Tel.: +49 89 9270 2201; fax: +49 89 9270 2295.

⁴ Tel.: +49 89 7095 6782; fax: +49 89 7095 6780.

⁵ Tel.: +49 99 1380 3601; fax: +49 99 1380 3602.

by a nidus surrounded by sclerotic bone with a size of usually less than 15 mm [1]. Radiography shows a radiolucent, sometimes centrally calcified nidus, surrounded by sclerosis and periosteal bone reaction. Various imaging modalities, such as radiography bone scintigraphy and magnet resonance imaging (MRI) enable for diagnosing OO computed tomography (CT) is highly useful by depicting the nidus as well as the surrounding sclerosis and periosteal bone reactions [2,3]. OO composes 10% of all benign bone tumors [4] and is associated with pain, which classically worsens at night and responds well to salicylates. Even though 75% of all OO are diagnosed in children and young adults, they may even occur in the mature skeleton up to 70 years of age [5]. Frequently, OO is located in the cortex of long bones. Frequent sites are femur or tibia (50%), while 10% are diagnosed to be in vertebrae [1]. The central nidus, a hallmark of OO contains osteoblasts and osteoid as well as nerves and vessels in the periphery of the lesion.

For the treatment of OO surgery, conservative treatment with nonsteroidal antiphlogistics and percutaneous interventions are

potential options. Surgery is frequently associated with major morbidity and a prolonged period of recovery (especially after en-bloc resection of osteoid osteoma in weight bearing bones), while long-term drug administration may result in gastrointestinal side effects and is not well tolerated by patients.

Rosenthal was the first to describe radiofrequency ablation (RFA) as a minimally invasive therapeutical option for the treatment of OO [6]. Since then, several studies have been published describing the effects of RFA regarding outcome and side effects. However, few larger series have been published and the duration of follow up is very variable.

Therefore the purpose of our study is to report our experience concerning the technical and clinical success, minor and major complications and especially long-term outcome after an observation period of up to 5 years after RF ablation of OO.

2. Material and methods

Patients were treated with RFA, if they had a typical history of pain, typically occurring during the night with relief after administration of nonsteroidal antiphlogistic drugs and if morphological features typical of OO were detected in radiological imaging. All patients had been evaluated by an experienced orthopaedic surgeon (HRD) prior to the treatment. Within a 5-year period (2003–2008) 39 patients were treated with RFA at our institution. The patients' cohort consisted in 23 males and 16 females with an age of 7–53 years (mean 18.7 years, median 17 years) at the time of the treatment. Patients' characteristics are summarized in detail in Table 1. In these 39 patients 39 OO were treated. The lesions were

located in the femur and femoral head ($n = 20$), the tibia ($n = 10$) and the spine ($n = 5$). Further localizations included the humerus ($n = 1$), the radius ($n = 1$), the talus ($n = 1$) and the pelvis ($n = 1$). Most of the osteoid osteoma treated were cortically located (36 of 39) and only 3 were located medullary. The mean lesion diameter was 6 mm. In 29 of 39 (74%) patients a biopsy immediately prior to the treatment was obtained.

At least 24 h prior to the treatment all patients or their legal guardian had to give written informed consent after extensive explanation of the planned therapeutic intervention, alternative therapeutical options (surgery, CT guided minimally invasive surgery, CT guided alcohol instillation and pharmaceutical treatment) and possible complications. The approval of a local IRB was not necessary due to the character of the study as a retrospective analysis.

In children and adolescents, RFA was generally performed under general anaesthesia. Due to the fact, that according to our hospital's policy all radiofrequency ablations of liver or kidney tumors have to be done under conscious sedation and we perform up to 100 of these treatments a year, we are very experienced in pain management during interventions. For this reason, conscious sedation was preferred in adults. 9 of 39 treatments were performed under conscious sedation using midazolam (Dormicum®, Roche – Pharma, Germany) and piritramide (Dipidolor®, Janssen-Cilag, Germany) together with local anaesthesia (Scandicain®, Astra-Zeneca, Germany). Pulse and oxygen saturation were measured constantly during the procedure in all patients using pulse oximetry. Oxygen was given on demand via a face mask. The other 30 procedures were performed under general anaesthesia mostly due to the fact

Table 1
Data of the treated patients including system used and follow up (months).

Patient no.	Sex	Age	Needle type	Localization	Follow up (months)
1	f	16	Starburst (RITA)	Radius	61
2	f	47	Cool Tip (Radionics)	Collum femoris	57
3	f	53	Starburst (RITA)	Femur	56
4	m	27	Cool Tip (Radionics)	Femoral head	55
5	m	33	Starburst (RITA)	Femur	55
6	m	32	Cool Tip (Radionics)	Pedicle L4	55
7	m	40	Starburst (RITA)	Talus	52
8	f	11	Cool Tip (Radionics)	Pedicle L5	51
9	f	11	Starburst (RITA)	Pedicle L5	50
10	m	20	Starburst (RITA)	Femur	50
11	m	14	Cool Tip (Radionics)	Tibia	49
12	m	12	Cool Tip (Radionics)	Femur	46
13	m	14	Starburst (RITA)	Pedicle Th 11	40
14	m	10	Starburst (RITA)	Femur	38
15	f	12	Starburst (RITA)	Tibia	36
16	f	11	LeVein (Boston)	Tibia	34
17	m	10	SDE (RITA)	Collum femoris	33
18	m	11	SDE (RITA)	Tibia	33
19	f	13	SDE (RITA)	Femur	32
20	m	21	SDE (RITA)	Collum femoris	32
21	m	18	SDE (RITA)	Tibia	31
22	f	28	SDE (RITA)	Femur	27
23	m	30	LeVein (Boston)	Pedicle Th 12	23
24	m	7	LeVein (Boston)	Collum femoris	22
25	w	9	LeVein (Boston)	Collum femoris	22
26	f	17	SDE (RITA)	Collum femoris	21
27	m	21	LeVein (Boston)	Femur	21
28	m	10	SDE (RITA)	Femur	21
29	m	10	SDE (RITA)	Tibia	17
30	f	11	SDE (RITA)	Collum femoris	16
31	m	18	SDE (RITA)	Tibia	12
32	m	14	LeVein (Boston)	Collum femoris	12
33	m	16	SDE (RITA)	Humerus	5
34	f	24	SDE (RITA)	Os ischiadicum	5
35	m	19	LeVein (Boston)	Femur	5
36	f	14	SDE (RITA)	Tibia	4
37	m	21	SDE (RITA)	Tibia	4
38	m	12	Celon ProSurge micro	Tibia	4
39	f	16	SDE (RITA)	Femur	1

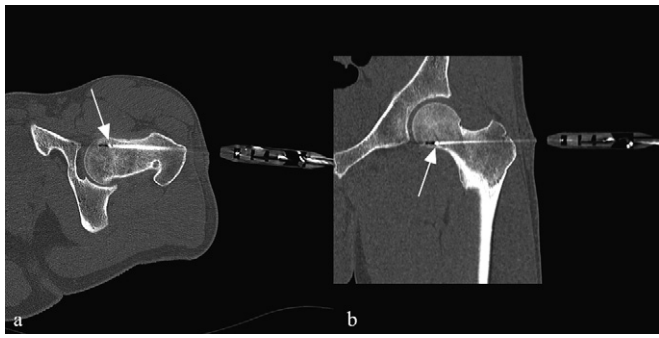


Fig. 1. RFA of an OO located in the femoral neck. Due to the proximity of the neurovascular bundle and the joint capsule a transfemoral approach was used to avoid any harm to critical structures.

that a surgical drill had to be used to reach the nidus of the OO or patients were young and the requested compliance could not be anticipated. Depending on the localization of the osteoid osteoma, patients were positioned on the CT table in a prone, oblique or supine position. In general, the shortest distance through the bone was selected for access. However, if such an approach was considered unsafe due to proximity to neurovascular structures, joint capsule or if the approach was technically difficult, the lesion was reached by drilling from the opposite side of the bone (Fig. 1a and b). All procedures were performed using CT-fluoroscopy using single slice, 4 slice, 16 slice, 64 slice and 128 slice MDCT, respectively (Somatom Plus 4, Sensation 4, Sensation 16, Sensation 64, Definition AS, Siemens Medical Solutions, Forchheim, Germany). Most patients suffering from OO are children, adolescents and young adults and therefore it is most important to contain the radiation exposure. For this reason the hand-care™ mode and a tube current for CT fluoroscopy as low as possible (12–20 mAs) was applied to reduce radiation exposure to the interventionalist and the patient to the lowest amount reasonable. 26 patients were treated using the monopolar RITA Starburst XL or SDE electrode (RITA Medical Systems, Mountain View, California, USA) with nine or three deployable electrodes, respectively. In 7 patients a monopolar, multitined expandable LeVein electrode (Radiotherapeutics, Boston Scientific Corporation, Natick, Massachusetts, USA) was used with the smallest diameter (2 cm) of the expandable electrode available. In 6 patients the internally cooled, needle shaped Cool Tip electrode (Tyco healthcare, Neustadt, Germany) and in 1 patient a bipolar electrode (Celon ProSurge micro, Celon, Teltow, Germany) was used. The access path was created under CT fluoroscopic guidance either by using a 14 Gauge bone biopsy cannula (Somatex Spicut®, Teltow, Germany) or with the help of a drill or power drill (Colibri, Synthes, Umkirch, Germany). If a drill or power drill was used, the skin was protected by using a protection sleeve. After creating the access, the biopsy cannula was removed and a biopsy was obtained for harvesting material for histopathologic examinations. The RF electrode was inserted using CT fluoroscopy via the access path created. Depending on the generator used, completion of the ablation procedure was defined either by reaching the target temperature (80–95 °C in average of the five/three thermocouples within the array or on the tip of the electrode) and holding it for at least 6–8 min or by reaching the so called “roll-off” (i.e. the significant increase of impedance resulting in the loss of AC flow) twice indicating a complete coagulation necrosis. Cooling of the skin using sterile draped ice packs was performed in OO adjacent to the skin (tibia, radius). An additional needle was inserted for saline flushing of the nerves roots if the OO was close to neural structures (spine) (Fig. 2a and b) as described by Gangi et al. [7]. When the treatment was completed, the electrode array was retracted and the electrode was removed. If necessary, the incision of the skin was sutured and a sterile drape of the skin was

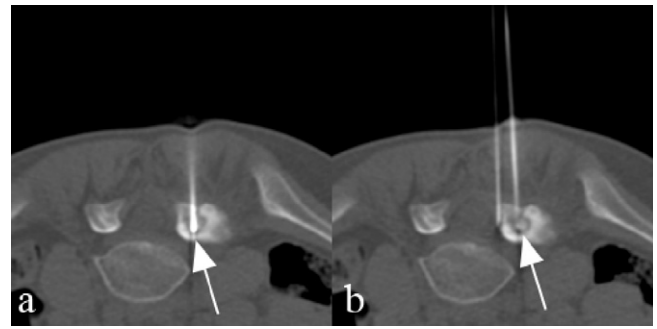


Fig. 2. 11 years old girl suffering from an osteoid osteoma of the vertebral articular process L5 treated with a Cool Tip electrode (arrow). Due to the proximity of the nerve route, a second needle (double arrow) was inserted and a continuous saline flushing of the adjacent structure was performed in order to prevent for nerve injury due to heat.

performed. During the intervention all patients received a single intravenous shot of 2 g mezlocillin (Baypen, Bayer AG, Leverkusen, Germany) comparable to the approach used by the orthopaedic surgeons to reduce the probability of a procedure related infection.

Procedures were considered to be technically successful if the electrode was placed centrally in the nidus and if the target temperature was reached and maintained.

According to our hospitals policy patients were discharged not at the same day, but 24 h after treatment from the orthopaedic ward. In case the lesions were located in the weight bearing bones they were instructed to avoid sports for at least 3 months; all other daily activities were allowed immediately after discharge. Moreover, they were asked to show up again, if pain did not significantly decrease or if adverse effects would occur. The follow up period has a maximum of 61 months (1–61 months, median 32 months, mean 30, 5 months).

3. Results

In 29 of 39 patients a biopsy was obtained successfully prior to the treatment. In the other 10 patients a biopsy was either not possible due to the hard surrounding sclerosis of the bone or the histopathologic specimen were too small for a reliable histologic diagnosis. In 14 of 29 biopsies histology confirmed the diagnosis “osteoid osteoma” (positive rate 48%), while in 15 of 29 biopsies (52%) only non-specific findings were obtained. There was no difference in the mean size of the diameter of the OO of both groups, nor were there differences in localization of the lesion.

In all except 1 patient we were able to penetrate the sclerotic rim and position the RF electrode centrally in the nidus. All 38 of 39 procedures could therefore be completed and were considered as technically successful. In 1 patient RFA could not be performed due to a complication regarding the drill—as described below. Immediate clinical success was achieved in 37 of the remaining 38 patients. In one 11-year-old girl suffering from an OO of the lumbar vertebra L5 pain was not significantly reduced after the first treatment and therefore a second RF ablation was performed 4 weeks later (Fig. 2a and b). The second RF ablation was successful in terms of a complete response and after the second ablation long-term clinical success (after a follow up of 50 months) was achieved. In 36 of the 38 patients an immediate and long-term success regarding pain relief was obtained at a median follow up time of 32 months (ranging from 1 to 61 months). However, in 2 patients a relapse of the symptoms similar to that experienced on initial clinical presentation developed after 14 and 32 months, respectively. Both patients were treated with a second RF ablation and are currently asymptomatic. The number of treatments did not exceed 1 per patient due to the fact that OO are very small in size and therefore an overlapping RF

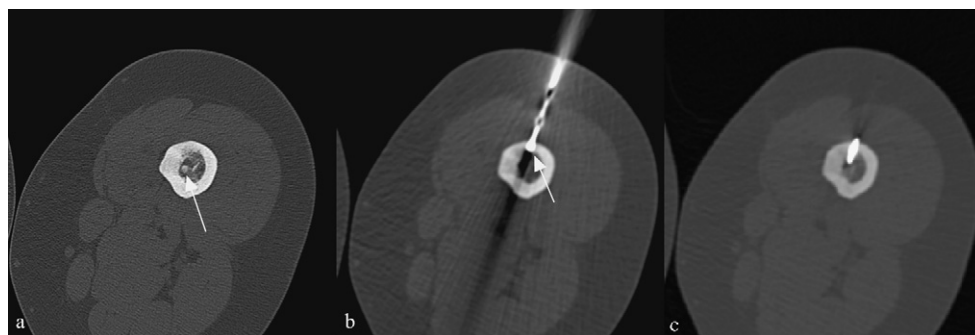


Fig. 3. (a) 53 years old female patient suffering from an osteoid osteoma of the femur. The patient had previously undergone several resections, however without long-term effect. (b and c) Due to the excessive reactive sclerosis the access path had to be created with a surgical drill. After successful drilling a distance of about 1.5 cm the drill broke and the drill bit remained in the bone.

volume comparable to the approach for larger soft tissue tumors was not necessary. The average procedure time was between 60 and 120 min from the time the patient entered the CT suite (including anaesthesia and the treatment itself). The time varied considerably depending on the patient's age, the anaesthesiologist involved, the location of the OO and the thickness of the sclerosis surrounding the nidus.

There were two major complications requiring consecutive surgery. One occurred in an adult female patient with a long-term history of OO. This OO was located in the femur and multiple surgical attempts had been made to remove the nidus. Due to the extensive sclerosis surrounding the nidus (Fig. 3a–c) the access path had to be created with a surgical hand drill. After successful drilling a distance of about 1.5 cm the drill broke and a fragment of the drill remained in the bone and the surrounding soft tissue making a surgical removal of the drill fragment mandatory. However, this accident was of some advantage for the patient, because by removing the drill fragment it was possible to remove the OO completely using the fragment as a marker for the en-bloc resection. Another major complication after RFA of an OO in the tibia was a soft tissue infection along the needle path with the need for a prolonged i.v. administration of antibiotics and a later surgical resection of the adjacent soft tissues. Moreover, two minor complications occurred. In 1 patient with an OO of the femur a large hematoma surrounding the needle entry point developed, which resolved spontaneously without any therapy. Another patient, a 9-year-old girl with an OO in the femoral neck suffered from prolonged pain for 2 weeks after RFA treatment. It resolved completely under symptomatic therapy (Fig. 4a–d).

No treatment related deaths, no anaesthesia related complications and no fractures of weight bearing bones or other late complications occurred. Furthermore, no instances of skin burn next to the electrode entry or in the area of the grounding pads and no neurovascular compromise developed.

4. Discussion

The data analysis of our patients demonstrated a clinical success rate of 92% (35/38) for the initial RF treatment which is in good correlation with other published studies [8,9]. In the patient with a recurrence of pain (1/38) after 4 weeks and the patients (2/38) with a recurrence during long-term follow up (14 and 32 months, respectively), the second RF-treatment was clinically successful and no patient had further complaints. The probability of an immediate (within the first month) recurrence is equivalent with a persistence of symptoms as published in literature [9] is up to 12%. The 9-year-old girl with ongoing pain in our series had an OO within the pedicle of L5 adjacent to the respective nerve root. Therefore, the first ablation was performed with very high precaution and one possible

reason for the incomplete or insufficient ablation might be due to the reduced ablation time because we were afraid of harming a nerve root. The second – then successful – ablation was done in a conventional manner with a target temperature of 85 °C and an ablation period of 8 min—as suggested by many authors [1,10]. This is one of the advantages of RFA that it can easily be repeated. If there is a failure of the first ablation with a relapse of symptoms, the success rate of a second RF ablation is near to 100%. In our series no case of a third ablation due to ongoing pain was required in accordance with other reports.

Late recurrence after surgical therapy may occur even after more than 10 years [11] and for RF ablation late recurrence was reported in up to 11% of patients with the latest recurrence described after 44 months [5]. There is one recent study [12] showing only a non-diaphyseal location of the OO as an independent risk factor and at least a trend to a higher recurrence rate for OO larger than 1 cm in size. Another study proves the size of the OO as only independent risk factor for an incomplete ablation with a significant higher recurrence rate for OO's larger than 10 mm, while location, sex, calcification and coagulation time were not identified as risk factors [13]. The authors of this study used a RF electrode with a 5-mm active tip, therefore the number of needle positions (composite ablation technique) was a significant factor for a decreased risk for symptom relapse especially in larger osteoidosteoma. In our series, the patients with the recurrence of symptoms suffered from an OO of the tibia and the femur, respectively. Both lesion were quite large in size (9 and 12 mm) and were treated with only one single needle position.

In our patient cohort we had two major complications, making a further surgical therapy necessary. In one patient the surgical drill broke and the drill fragment had to be removed surgically. It is well known, that especially patients with thick sclerotic bone are at risk of this complication due to marked heating of the needle as well as choking of the needle with cortical bone. A possible relief could be to change the needle part way through the drilling for a fresh needle in order to avoid breaking of the drill. However, due to surgical data, breakage of drill is the most common defect of surgical instruments and occurs in about 3 of 1000 internal fixations [14]. Especially during internal fixation of humeral or femoral fractures the necessity to drill cortical bone at an incident angle similar to that we used, leads to a bending of the drill bit and is therefore responsible for the breakage [15]. There is little evidence that retention of the drill bit fragment in the bone causes any harm to the patients and therefore in most cases the fragment is left in place. In this particular patient further surgery was performed because during the removal of that piece of the drill the OO could be completely removed using the fragment as a marker for the resection. Therefore, the only “real” major complication was an infection of the needle tract in spite of working under sterile conditions and using

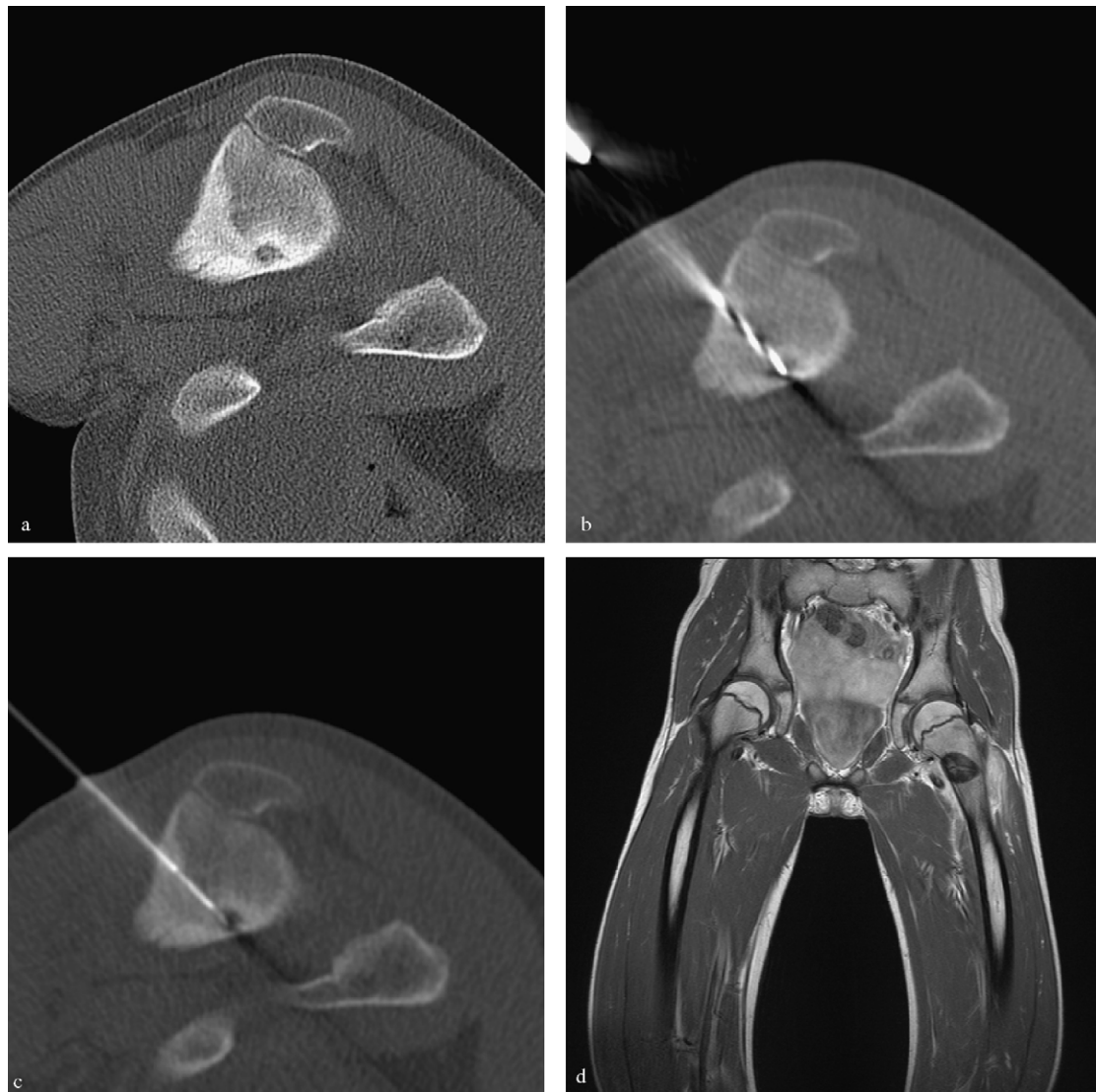


Fig. 4. (a) 9 years old girl suffering from an OO of the femoral neck (minor trochanter). (b) The intervention was performed under general anaesthesia. First, an access path was created using a surgical drill. (c) After creating the access a RITA SDE electrode was inserted and the RF ablation was performed at a target temperature of 85 °C over a period of 8 min. (d) Patient had prolonged pain—therefore a MRI examination was performed 1 week after the initial treatment to rule out any severe complications. Extensive soft tissue edema was seen adjacent to the proximal femur. No signs of an abscess formation. The coagulation necrosis subsequent to RFA is depicted as an area of low signal intensity.

i.v. antibiotics during the intervention. The infected tissue had to be removed surgically—however, no evidence of an osteomyelitis or osteitis did occur and the patient recovered without any remaining problems. Minor complications were found in 2 patients—in 1 patient a hematoma and in another prolonged pain for 2 weeks which resolved spontaneously under symptomatic treatment.

In our cohort were 5 patients suffering from OO of the spine who were treated without any complications and with good clinical results. There are different opinions regarding the treatment of OO located in the pedicle or close to the nerve roots. Rosenthal et al. [8] describe the treatment of these OO as not advisable because there is an increased risk of thermal injury of the nerves, while Gangi et al. [7] and Martel et al. [16] found the therapy safe, and hypothesized that the surrounding sclerosis and the cortical bone acts as an effective insulator. Therefore we conclude that nerves and other structures are not at risk for any heat related damage. Furthermore, we used a cool bath technique – as described by Gangi [7] – with a slow infusion of saline of room temperature at a flow rate of 60 ml/h via an additional needle. Another technique applied by us to avoid heat related tissue necrosis especially in patients

with OO in the radius or tibia is the sterile draping of commercially available cool packs. The cool packs were positioned around the needle shaft at the entry point and secured a sufficient cooling of the overlying skin and soft tissues.

Unlike in most other published studies [17–19], we tried to obtain biopsies prior to the treatment to confirm the diagnosis. In less than 50% of samples a correct—positive histological diagnosis of OO was obtained. However, the imaging signs and clinical symptoms can be regarded as pathognomonic so that it is adequate to perform therapy in the absence of a histopathological confirmation of the diagnosis [20]. Even in the largest published series which includes 263 patients treated with RF ablation [8] with 271 biopsies obtained prior to the treatment, nearly 30% of all biopsies did not confirm the diagnosis of OO. Other studies even describe the correct positive rate to be as low as 36% [2,21]. Furthermore, it is well known, that findings at needle biopsies in primary bone tumors may have a substantial false-negative rate and especially in OO non-diagnostic biopsy findings are very common even after surgical resection [22]. This is – beside the small size of the specimen obtained with needle biopsy – due to the small diameter of the

nidus, which is the only part of the OO which allows for evaluation by histopathology whereas the surrounding bone sclerosis is non-specific. Therefore, we did not exclude patients from RF-treatment or from this study in analogy to other authors [8,20], if clinical and imaging findings were conclusive and indicative for the diagnosis of an osteoid osteoma.

Despite the massive reduction of the tube current to 12–20 mAs at a voltage of 120 kV during CT fluoroscopy to reduce the radiation exposure to the patients image quality was good enough to perform all procedures successfully. Due to the high inherent contrast of the nidus versus the adjacent sclerotic bone, radiation could be greatly reduced without compromising the visibility of the anatomical structures as well as the metal biopsy needle, surgical drill and RF electrode as described by Cantwell et al. [23].

We used various commercially available RF-systems for RF ablation of OO. Of course, the groups for the different RF systems are too small for statistical analysis; however, we could not detect any differences in our series regarding the outcome, RF time, overall procedure time and complication rate after treatment. Therefore we assume that the all systems employed allow for tissue devascularization and reliable coagulation of the nidus. The clinical success rates for monopolar, bipolar and laser induced thermal therapy (LITT) reported in literature range between 92% and 95% [7,8,18] and comparable results are published for the different monopolar systems [24,25]. Obviously, neither the electrode (deployable vs. needle shaped) nor the system (monopolar vs. bipolar, RF vs. LITT) has any impact on the patients outcome.

An advantage of RF ablation over other treatment modalities is the lower costs of the procedure. Lindner et al. [26] compared the costs by adding procedural costs, costs for hospitalisation and treatment of complications in 91 patients treated with different methods. Even though they did not include the social costs for inactivity and disability they found RF ablation with a total cost of \$6583 the least expensive method compared to en-bloc resection, marginal resection, intra-lesional curettage and CT guided drilling with additional costs of \$7243, \$4274, \$4409 and \$2006, respectively.

5. Conclusion

Thermal ablation is a minimally invasive treatment option for patients suffering from OO which provides excellent immediate clinical results at a low complication and relapse rate. Patients with a relapse should be treated with a second RF ablation rather than with surgical resection. RFA reduces the hospital stay and rehabilitation period of the patient and is more cost effective than any other therapy. The results achieved are not dependent on the generator or system used for heating and a biopsy prior to the treatment is not mandatory if confident diagnosis can be made based on clinical symptoms and imaging findings. Therefore, surgical resection should only be performed in the rare cases in which the lesion is inaccessible by a percutaneous approach or in patients with more than one relapse after RFA.

References

- [1] Pinto CH, Taminiau AH, Vanderschueren GM. Technical considerations in CT-guided radiofrequency thermal ablation of osteoid osteoma: tricks of the trade. *AJR* 2002;179(6):1633–42.
- [2] Assoun J, Railhac JJ, Bonneville P, et al. Osteoid osteoma: percutaneous resection with CT guidance. *Radiology* 1993;188(2):541–7.
- [3] Assoun J, Richardi G, Railhac JJ, et al. Osteoid osteoma: MR imaging versus CT. *Radiology* 1994;191(1):217–23.
- [4] Greenspan A. Benign bone-forming lesions: osteoma, osteoid osteoma, and osteoblastoma. Clinical, imaging, pathologic, and differential considerations. *Skeletal Radiol* 1993;22(7):485–500.
- [5] Cantwell CP, Obyrne J, Eustace S. Current trends in treatment of osteoid osteoma with an emphasis on radiofrequency ablation. *Eur Radiol* 2004;14(4):607–17.
- [6] Rosenthal DI, Alexander A, Rosenberg AE, et al. Ablation of osteoid osteomas with a percutaneously placed electrode: a new procedure. *Radiology* 1992;183(1):29–33.
- [7] Gangi A, Alizadeh H, Wong L, et al. Osteoid osteoma: percutaneous laser ablation and follow-up in 114 patients. *Radiology* 2007;242(1):293–301.
- [8] Rosenthal DI, Hornicek FJ, Torriani M, et al. Osteoid osteoma: percutaneous treatment with radiofrequency energy. *Radiology* 2003;229(1):171–5.
- [9] Vanderschueren GM, Taminiau AH, Obermann WR, et al. Osteoid osteoma: clinical results with thermocoagulation. *Radiology* 2002;224(1):82–6.
- [10] Rosenthal DI, Hornicek FJ, Wolfe MV, et al. Percutaneous radiofrequency coagulation of osteoid osteoma compared with operative treatment. *J Bone Joint Surg* 1998;80(6):815–21.
- [11] Regan MW, Galey JP, Oakeshott RD. Recurrent osteoid osteoma. Case report with a ten-year asymptomatic interval. *Clin Orthop Relat Res* 1990;253:221–4.
- [12] Cribb GL, Goude WH, Cool P, et al. Percutaneous radiofrequency thermocoagulation of osteoid osteomas: factors affecting therapeutic outcome. *Skeletal Radiol* 2005;34(11):702–6.
- [13] Vanderschueren GM, Taminiau AH, Obermann WR, et al. Osteoid osteoma: factors for increased risk of unsuccessful thermal coagulation. *Radiology* 2004;233(3):757–62.
- [14] Hirt U, Auer JA, Perren SM. Drill bit failure without implant involvement—an intraoperative complication in orthopaedic surgery. *Injury* 1992;23(Suppl. 2):S5–16.
- [15] Price MV, Molloy S, Solan MC, et al. The rate of instrument breakage during orthopaedic procedures. *Int Orthop* 2002;26(3):185–7.
- [16] Martel J, Bueno A, Nieto-Morales ML, et al. Osteoid osteoma of the spine: CT-guided monopolar radiofrequency ablation. *Eur J Radiol* 2008 May 31, Epub ahead of print.
- [17] Gebauer B, Tunn PU, Gaffke G, et al. Osteoid osteoma: experience with laser- and radiofrequency-induced ablation. *Cardiovasc Interv Radiol* 2006;29(2):210–5.
- [18] Mahnken AH, Tacke JA, Wildberger JE, et al. Radiofrequency ablation of osteoid osteoma: initial results with a bipolar ablation device. *J Vasc Interv Radiol* 2006;17(9):1465–70.
- [19] Martel J, Bueno A, Ortiz E. Percutaneous radiofrequency treatment of osteoid osteoma using cool-tip electrodes. *Eur J Radiol* 2005;56(3):403–8.
- [20] Campanacci M, Ruggieri P, Gasbarrini A, et al. Osteoid osteoma. Direct visual identification and intralesional excision of the nidus with minimal removal of bone. *J Bone Joint Surg* 1999;81(5):814–20.
- [21] Lindner NJ, Ozaki T, Roedel R, et al. Percutaneous radiofrequency ablation in osteoid osteoma. *J Bone Joint Surg* 2001;83(3):391–6.
- [22] Sim FH, Dahlin CD, Beabout JW. Osteoid-osteoma: diagnostic problems. *J Bone Joint Surg* 1975;57(2):154–9.
- [23] Cantwell CP, Kenny P, Eustace S. Low radiation dose CT technique for guidance of radiofrequency ablation of osteoid osteoma. *Clin Radiol* 2008;63(4):449–52.
- [24] Cantwell CP, O'Byrne J, Eustace S. Radiofrequency ablation of osteoid osteoma with cooled probes and impedance-control energy delivery. *AJR* 2006;186(Suppl. 5):S244–8.
- [25] Venbrux AC, Montague BJ, Murphy KP, et al. Image-guided percutaneous radiofrequency ablation for osteoid osteomas. *J Vasc Interv Radiol* 2003;14(3):375–80.
- [26] Lindner NJ, Scarborough M, Ciccarelli JM, et al. CT-controlled thermocoagulation of osteoid osteoma in comparison with traditional methods. *Zeitschrift für Orthopädie und ihre Grenzgebiete* 1997;135(6):522–7.